

## Colocutaneous Fistula in the Untreated Elderly with Quiescent Crohn's Disease

Lei Liu<sup>1,2,3</sup> | Si-Wen Qin<sup>1,2,3</sup> | Wei Liu<sup>1,2,3\*</sup>

\*Correspondence: Wei Liu

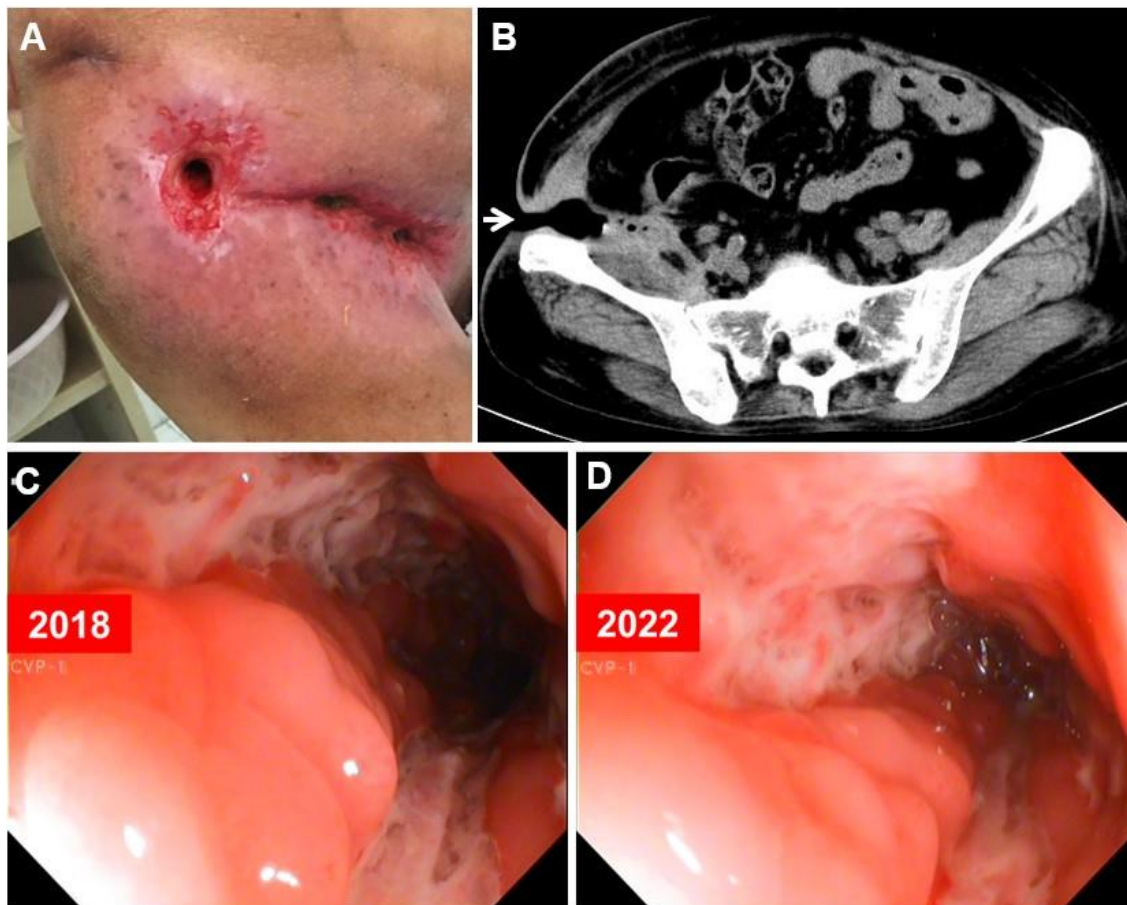
Address: <sup>1</sup>The First College of Clinical Medical Science, China Three Gorges University, Yichang, China; <sup>2</sup>Institute of Digestive Disease, China Three Gorges University, Yichang, China; <sup>3</sup>Department of Gastroenterology, Yichang Central People's Hospital, Yichang, China.

e-mail ✉: [liuwei@ctgu.edu.cn](mailto:liuwei@ctgu.edu.cn)

Received: 30 May 2022; Accepted: 06 June 2022

Copyright: © 2022 Liu L. This is an open-access article distributed under the terms of the Creative Commons Attribution License, which permits unrestricted use, distribution, and reproduction in any medium, provided that the original work is properly cited.

### Clinical Image



**Figure 1:** Colocutaneous fistula overflowed with continually loose bloody stools was observed in the right groin (Figure 1A), which was consistent with abdominal computed tomography imaging (Figure 1B). Colonoscopy findings from 2018 to 2022 (Figure 1C, 1D).

A 61-year-old woman was hospitalized with a 1-month history of fatigue. Her past medical history was Crohn's disease. For the previous 20 years, the patient had been free of treatment for Crohn's disease except for punctual blood transfusion once a year. On examination, colocutaneous fistula overflowed with continually loose bloody stools was observed in the right groin (Fig. 1A), which was consistent with abdominal computed tomography imaging (Fig. 1B). Colocutaneous fistula was initial presentation of the colonic Crohn's disease for her, which was further confirmed by colonoscopy and histological examination 20 years ago. Until now, this patient refused to take any therapeutic strategy including mesalazine, prednisone and infliximab. Laboratory test showed a hemoglobin level of 5.10 g per deciliter (normal range, 1.35 to 1.75). After a well-informed discussion of options for interventions with the patient, the decision was not made to treat this potentially quiescent disease identified by colonoscopy findings within 4 years (Fig. 1C & 1D) (Boyapati *et al.*, 2018). She only received blood transfusion and oral iron supplementation, the same as before, and then was discharged in stable condition.

**Conflicts of Interest:** The authors have no conflicts of interest to declare.

**Ethical Statement:** The authors are accountable for all aspects of the work in ensuring that questions related to the accuracy or integrity of any part of the work are appropriately investigated and resolved. Written informed consent was obtained from the patient for publication of this "GI Image".

**Author's contributions:** Collection of data and writing: Lei Liu; Manuscript preparation: Si-Wen Qin; Final approval of the manuscript: Wei Liu

## References

Boyapati RK, Torres J, Palmela C, Parker CE, Silverberg OM, Upadhyaya SD, Nguyen TM, Colombel JF. Withdrawal of immunosuppressant or biologic therapy for patients with quiescent Crohn's disease. *Cochrane Database Syst Rev* 2018; 5: Cd012540.