

An Unexpected Finding: Gastric Neuroendocrine Neoplasm

Sheng-Lan Du^{1,2,3} | Yan Zhang^{1,2,3} | Wei Liu^{1,2,3*}

*Correspondence: Wei Liu

Address: ¹The First College of Clinical Medical Science, China Three Gorges University, Yichang, China; ²Institute of Digestive Disease, China Three Gorges University, Yichang, China; ³Department of Gastroenterology, Yichang Central People's Hospital, Yichang, China

e-mail ✉: liuwei@ctgu.edu.cn

Received: 09 April 2022; Accepted: 12 April 2022

Copyright: © 2022 Lan Du S. This is an open-access article distributed under the terms of the Creative Commons Attribution License, which permits unrestricted use, distribution, and reproduction in any medium, provided that the original work is properly cited.

Clinical Image

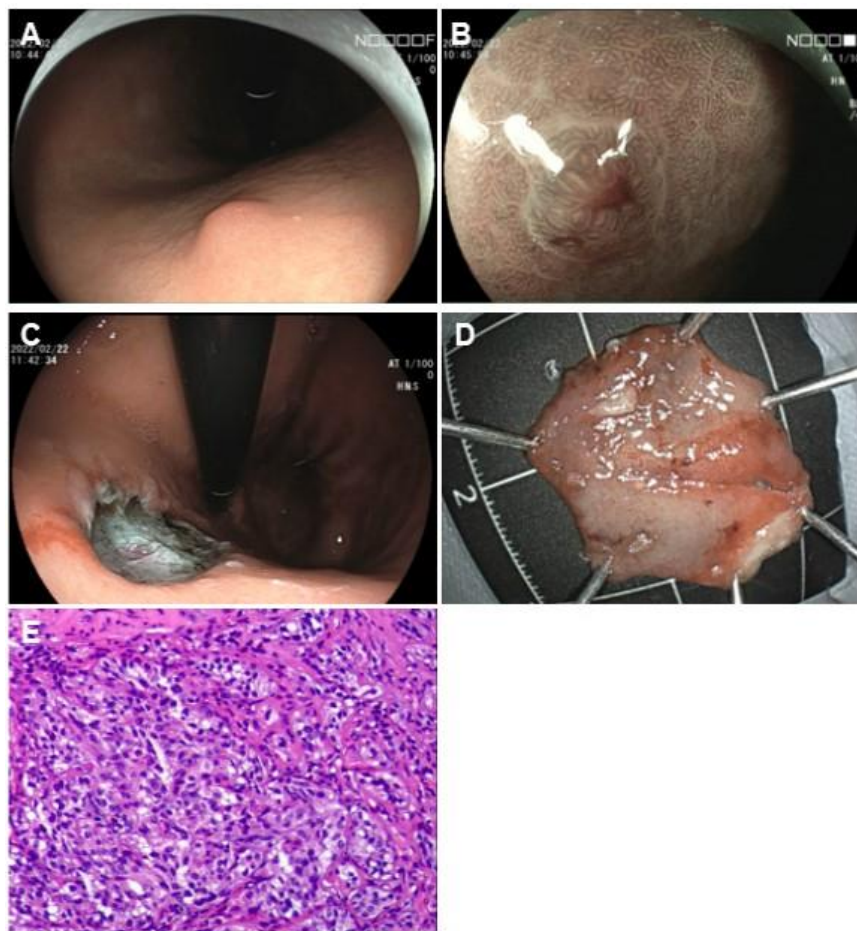


Figure 1: An Unexpected Finding: Gastric Neuroendocrine Neoplasm. A: Conventional endoscopic image with white light revealed a hemispherical reddish submucosal tumor; B: Magnifying endoscopic image with narrow band imaging revealed gastric pit structures present on the surface of the tumor; C, D: Endoscopic submucosal dissection was performed to remove the lesion; E: Histopathology of the specimen by hematoxylin and eosin staining.

A 43-year-old woman was admitted to the gastroenterology clinic because of a 1-year history of epigastric pain. She had no documented medical history. Her physical examination and *Helicobacter pylori* antigen detection revealed no remarkable abnormalities. Gastroscopy demonstrated a 0.8 cm nodule in the gastric greater curvature (Fig. 1A, B). Endoscopic ultrasound demonstrated a hypoechoic intramural structure in the second layer corresponding to the submucosal layer of the gastric wall. Endoscopic submucosal dissection was performed to remove the lesion (Fig. 1C, D). Histopathology of the specimen by hematoxylin and eosin staining (Fig. 1E) and the lesion staining strongly immunoreactive for chromogranin and synaptophysin were consistent with a well-differentiated grade 2 neuroendocrine neoplasm type 1 based on clinical characteristics of the patient, which was featured by a moderate proliferation index Ki67 around 5% in neoplastic cells. No etiology for her epigastric pain was found on gastroscopy examination. Gastric neuroendocrine neoplasms (g-NENs) are a heterogeneous group of tumours arising from enterochromaffin like cells and showing different clinicopathological features and behaviour, which increase in frequency partially due to increased use of endoscopy imaging (La Rosa and Vanoli, 2014). The diagnosis of g-NENs depends on histopathological investigation characterized by positively staining with chromogranin A and synaptophysin, which is taken by upper gastrointestinal endoscopy (Köseoğlu et al., 2021). Mitotic index and ki-67 proliferation index contribute to grading. The management, treatment and prognosis differ significantly between subtypes of g-NENs. Treatment options for g-NENs include endoscopic and surgical resection, and medical treatment with somatostatin analogues and chemotherapy. Type I g-NENs are managed with local endoscopic resection and surveillance, which usually have a good prognosis (Tsolakis et al., 2019). Follow-up endoscopic after 1 year confirmed no recurrence. However, the patient needed to be aware of potential occurring autoimmune gastritis due to the positive anti-parietal cell antibody although no signs of vitamin B12 deficiency anemia emerging.

Conflicts of Interest: The authors have no conflicts of interest to declare.

Ethical Statement: The authors are accountable for all aspects of the work in ensuring that questions related to the accuracy or integrity of any part of the work are appropriately investigated and resolved. Written informed consent was obtained from the patient for publication of this “GI Image”.

References

- Köseoğlu H, Duzenli T, Sezikli M. Gastric neuroendocrine neoplasms: A review. *World J Clin Cases* 2021; 9: 7973-7985.
- La Rosa S and Vanoli A. Gastric neuroendocrine neoplasms and related precursor lesions. *J Clin Pathol* 2014; 67: 938-948.
- Tsolakis AV, Ragkousi A, Vujasinovic M, Kaltsas G, Daskalakis K. Gastric neuroendocrine neoplasms type 1: A systematic review and meta-analysis. *World J Gastroenterol* 2019; 25: 5376-5387.