

Osteoid Osteoma of The Frontal Sinus: A Case Report

Hamoud Maarouf¹ | Msheik Ali^{2*}

*Correspondence: Msheik Ali

Address: ¹Neurosurgeon, ZHUMC, Lebanon; ²Neurosurgery resident, ZHUMC, Lebanese University, Lebanon

e-mail ✉: dr.alimsheik@gmail.com

Received: 11 July 2022; Accepted: 23 September 2022

Copyright: © 2022 Maarouf H. This is an open-access article distributed under the terms of the Creative Commons Attribution License, which permits unrestricted use, distribution, and reproduction in any medium, provided that the original work is properly cited.

ABSTRACT

An osteoid osteoma is a benign bone-forming tumor that usually causes nocturnal severe pain. The majority are found in the head and neck region and represent the most common benign neoplasm of the nose and paranasal sinuses. We report the case of a 14-year-old female patient admitted for refractory headache and diagnosed with an osteoid osteoma of the frontal sinus, which have been treated successfully using surgical intervention. As for our patient, en block wide excision was enough to resect the whole tumor as it was confined to the frontal sinus.

Keywords: *Osteoid Osteoma, Frontal Bone, Surgical Excision*

Introduction

With no malignant potential, an osteoid osteoma is a benign bone-forming tumor that usually causes nocturnal severe pain (Tepelenis *et al.*, 2021). NSAIDs are the drug of choice for analgesia of pain related to this condition. Osteoid osteomas represent 10% of all benign bone tumors (Dookie and Joseph, 2022). The majority are found in the head and neck region and represent the most common benign neoplasm of the nose and paranasal sinuses (Lund *et al.*, 2016). In review of reported cases, the incidence of osteoid osteomas in the frontal bone/sinus ranges from 35% up to 80% of cases (Shanavas *et al.*, 2013). We report the case of a 14-year-old female patient admitted for refractory headache and diagnosed with an osteoid osteoma of the frontal sinus, which have been treated successfully using surgical intervention.

Case Presentation

A 14-year-old female patient was received at the private clinic for severe headache, which goes back to 6 months prior to presentation. The patient has no past medical and surgical history. The pain is associated with mild nausea and is mainly at the frontal region of the skull radiating to the right orbit. No nasal secretions were reported. The patient and her parents denied recent infections, flu-like symptoms, fever, respiratory, gastrointestinal, and urinary symptoms.

The physical examination was normal. No neurological deficit was detected. The patient had normal visual acuity, eye movements and gait performance. The site of frontal sinus and bone pain reported was not tender, inflamed or erythematous.

Laboratory workup revealed normal blood count and differential, normal electrolyte levels, creatinine, pTT and INR. A computed tomography of the brain was done without contrast and revealed a bony mass in the frontal sinus; mostly right sided (Fig. 1 and Fig. 2). A magnetic resonance imaging of the brain was done without gadolinium and ruled out the presence of other brain lesions.

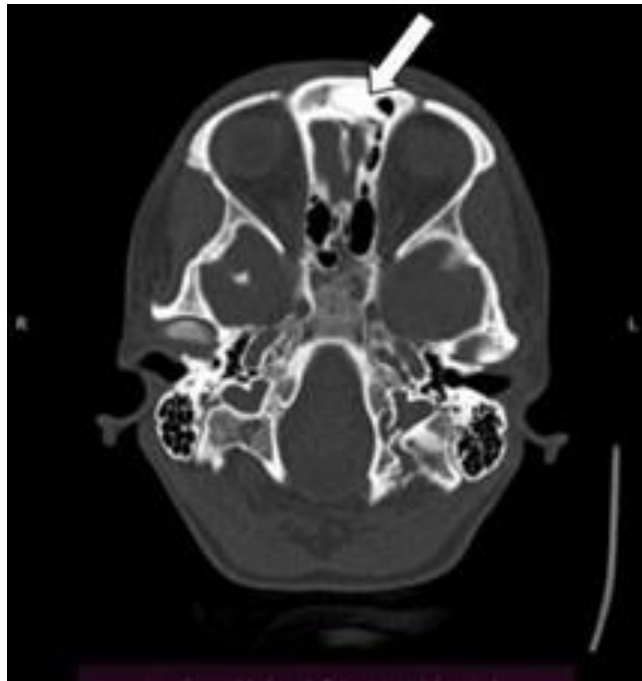


Figure 1: Axial view of a CT scan showing osteoid osteoma in right and left Frontal sinuses (white arrow).

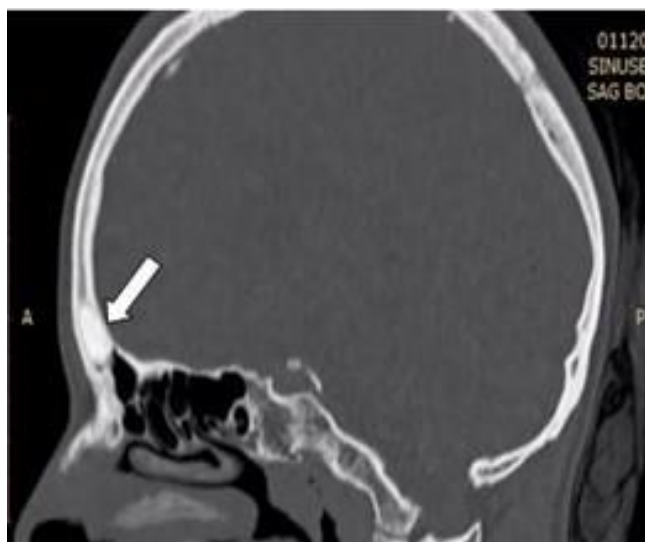


Figure 2: Sagittal view of a CT scan showing osteoid osteoma in right and frontal Frontal sinuses (white arrow).

Treatment

The patient was scheduled for frontal bone craniotomy for exploration and mass excision. Excision through the left eyebrow was done and exposure of the bony mass was done using craniotomy through the frontal bone into the frontal sinus. Excision of the mass was done “en bloc”. Gross examination correlated with an osteoid osteoma. The mass was sent to the pathology lab. The surgical procedure was complicated with mild ecchymosis of the left orbit. Otherwise, the patient was extubated with no complication and was kept hospitalized for 24 hours for close observation. She was then discharged on analgesia and advised to maintain proper follow up. The pathology results approved the preliminary diagnosis.

Discussion

Osteoid osteomas are benign tumors of osseous origin, which come third in place of incidence after non-ossifying fibromas and endochondromas (De Salvo *et al.*, 2022). They are slow growing and can occur in any bone of the face and the cranium either superficially or intraosseous⁶. With a size, typically less than 2 cm in diameter, an osteoid osteoma consists of a central radiolucent nidus and surrounding reactive osteosclerosis (Tepelenis *et al.*, 2021). Although the incidence of osteoid osteomas peaks in the second decade of life, more than 70% of patients are younger than 20 years of age (Tepelenis *et al.*, 2021). When an osteoma is suspected in long bones, an X-ray is requested. However, if the location is rather complex, a computed tomography is more beneficial. As for our patient, an additional MRI of the brain was essential to rule out associated brain lesions. Multiple pathologies can present as an osteoid osteoma. Those include an early stage of Ewing’s sarcoma, sclerosing osteitis, stress fracture, focal cortical bone abscess and bone infarction. Rare reports of metastasis from pulmonary adenocarcinomas, abnormal bone deposition as in osteopathia striata sclerosis in the frontal bone and desmoplastic fibromas (Lucke-Wold *et al.*, 2020) with cranial manifestation in children are examples of differential diagnoses of osteoid osteomas of the cranium. Although rare, consideration of those findings is mandatory.

Usually, medical treatment is the primary mode of care for osteoid osteomas of the long bones where the epiphysis is not affected (Rodriguez and Poussaint, 2010). Non-steroidal anti-inflammatory drugs (NSAIDs) and salicylates are the main option for analgesia of the pain associated with osteoid osteomas (Hasegawa *et al.*, 1993). As for our patient, the pain was controlled using acetyl salicylic acid. However, relapse of symptoms was rapid after discontinuation of analgesia. Larger osteomas with refractory symptoms or effect on bone growth are treated using surgical means; i.e. in most cases en bloc excision. To limit damage to surrounding tissues, percutaneous radio frequency ablation modalities are utilized (De Filippo *et al.*, 2018). However, the latter is still limited. As for our patient, en block wide

excision was enough to resect the whole tumor as it was confined to the frontal sinus.

References

De Filippo M, Russo U, Papapietro VR, Ceccarelli F, Pogliacomì F, Vaienti E, Piccolo C, Capasso R, Sica A, Cioce F, Carbone M, Bruno F, Masciocchi C, Miele V. Radiofrequency ablation of osteoid osteoma. *Acta Biomed* 2018; 89: 175-185.

De Salvo S, Pavone V, Coco S, Dell'Agli E, Blatti C, Testa G. Benign Bone Tumors: An Overview of What We Know Today. *J Clin Med* 2022; 11: 699.

Dookie AL and Joseph RM. Osteoid Osteoma. [Updated 2022 May 2]. In: StatPearls [Internet]. Treasure Island (FL): StatPearls Publishing; 2022 Jan-. Available from: <https://www.ncbi.nlm.nih.gov/books/NBK537279/?report=classic>

Hasegawa T, Hirose T, Sakamoto R, Seki K, Ikata T, Hizawa K. Mechanism of pain in osteoid osteomas: an immunohistochemical study. *Histopathology* 1993; 22: 487-491.

Lucke-Wold B, Samaka RM, Refaat BF, Zwayed ARH. Desmoplastic Fibroma of the Skull in an Infant: A Case Report. *Neurol Sci Neurosurg* 2020; 1: 108.

Lund VJ, Clarke PM, Swift AC, McGarry GW, Kerawala C, Carnell D. Nose and paranasal sinus tumours: United Kingdom National Multidisciplinary Guidelines. *J Laryngol Otol* 2016; 130: S111-S118.

Rodriguez DP and Poussaint TY. Imaging of back pain in children. *AJNR Am J Neuroradiol* 2010; 31: 787-802.

Shanavas M, Chatra L, Shenai P, Veena K, Rao P, Prabhu R. Multiple peripheral osteomas of forehead: report of a rare case. *Ann Med Health Sci Res* 2013; 3: 105-107.

Tepelenis K, Skandalakis GP, Papathanakos G, Kefala MA, Kitsouli A, Barbouti A, Tepelenis N, Varvarousis D, Vlachos K, Kanavaros P, Kitsoulis P. Osteoid Osteoma: An Updated Review of Epidemiology, Pathogenesis, Clinical Presentation, Radiological Features, and Treatment Option. *In Vivo* 2021; 35: 1929-1938.

Tepelenis K, Skandalakis GP, Papathanakos G, Kefala MA, Kitsouli A, Barbouti A, Tepelenis N, Varvarousis D, Vlachos K, Kanavaros P, Kitsoulis P. Osteoid Osteoma: An Updated Review of Epidemiology, Pathogenesis, Clinical Presentation, Radiological Features, and Treatment Option. *In Vivo* 2021; 35: 1929-1938.