

Newborn Endogenous Endophthalmitis Caused by Streptococcus Pneumoniae

Marina Laura Rodríguez-Rojo^{1*} | Enrique Alberto Criado-Vega¹ | Marta Illán-Ramos¹ | Juan Donate-Lopez² | Jose Martinez-Orgado¹ | Jose Tomás Ramos-Amador¹

*Correspondence: Marina Laura Rodríguez-Rojo

Address: ¹Department of Pediatrics. Hospital Clínico San Carlos. Madrid, Spain; ²Department of Ophthalmology. Hospital Clínico San Carlos. Madrid, Spain

e-mail ✉: marina.r.rojo@gmail.com; marinalaura.rodriguez@salud.madrid.org

ORCID-ID: <https://orcid.org/0000-0001-9804-8990>

Received: 20 August 2020; Accepted: 26 August 2020

Copyright: © 2020 Rojo MLR. This is an open-access article distributed under the terms of the Creative Commons Attribution License, which permits unrestricted use, distribution, and reproduction in any medium, provided that the original work is properly cited.

ABSTRACT

A case of a six days of life term newborn with suspicion of sepsis with meningeal involvement is described, in whom positivity for pneumococcal antigen in cerebrospinal fluid (CSF) was positive, associated with endophthalmitis with positivity for pneumococcal polymerase chain reaction (PCR) in vitreous humor. This case is significant because it represents a unique presentation in a neonate of pneumococcal meningitis with endophthalmitis. This case illustrates the importance of maintaining a high index of suspicion of eye involvement in cases of complicated bacterial meningitis and also highlights the utility of bacterial PCR in vitreous humor, as well as pneumococcal antigen testing in CSF as useful diagnostic tools in newborns.

Keywords: Case Report, Endophthalmitis, Streptococcus Pneumoniae, Newborn, Meningitis

Background

Streptococcus pneumoniae endophthalmitis in newborns is extremely rare. To the best of our knowledge, there is just one publication of endophthalmitis due to Streptococcus pneumoniae reported in 1975 (Weinstraub and Otto, 1972).

Case Presentation

A term appropriate weight for gestational age newborn is referred from a local hospital to our third-level neonatal intensive care unit (NICU) at six days of life suspecting sepsis with meningeal involvement and clinical seizures.

Pregnancy was well controlled from week 19 of gestation, with serologies showing positive rubella IgG antibodies and negative test for toxoplasma, hepatitis B, syphilis and HIV. Mother was 19-year-old with no previous medical problems, developing during pregnancy gestational diabetes and

hypothyroidism. Group B streptococcus screening cultures were also negative at 35 weeks. At 40 weeks of gestational age, intrapartum fever developed with 6 hours of membrane rupture. No prophylactic antibiotics were administered. Apgar scores at 1 and 5 minutes were 9 and 10, respectively, and the patient was discharged at 48 hours of life without incidents during the staying at the maternity unit.

The patient was taken to the emergency department at six days of life due to five hours of fever with a maximum temperature of 38.9 °C without any other associated symptomatology. There were no known sick contacts in the family.

She was admitted to the hospital to study the fever of unknown origin. During the 48 hours hospital admission she presented clonic movements of left limbs. Initial laboratory test showed: 6.820 leukocytes/ μ L (54,7% neutrophils), C-reactive protein 15,3 mg/dL and procalcitonin 0,96 ng/mL. The blood culture was preliminary informed as positive for *Streptococcus pneumoniae*, and later confirmed as negative when the patient had already been transferred. A lumbar puncture was performed unsuccessfully and, without biochemical or culture result, therapy with cefotaxime and ampicillin was initiated. Prior to transfer to our center a new blood test was performed showing increase of acute phase reactants: 19.640 leukocytes/ μ L (78.9% neutrophils) and C-reactive protein 23,7 mg/dL.

Upon arrival at our center, the patient was in good general condition with neurological examination showing mild hypertonia in the right lower limb.

Acyclovir was added to the treatment. A second lumbar puncture was performed successfully, with a positive test result for pneumococcal antigen in cerebrospinal fluid. The CSF analysis revealed 39 hematies/uL, 153 leukocytes/uL (99% mononuclears), 366 mg/dL proteins, 29 mg/dL glucose. CSF culture was negative.

Results of microbiology were returned showing negative blood culture and PCR negative for common respiratory viruses in nasopharyngeal aspirate. Ampicillin and acyclovir were withdrawn and cefotaxime maintained.

Two days after admission in our NICU, physical examination revealed a lack of light reflex in the left eye, along with lack of red reflex with the ophthalmoscope examination.

Electroencephalography (EEG) monitoring disclosed epileptic activity in the first hours of admission, controlled with antiepileptic treatment.

During her hospitalization, brain magnetic resonance were performed, showing lesions consistent with evolving ischemic strokes in both frontal lobes, right temporal and occipital lobes as well as in the

left cerebellar hemisphere. In addition, an alteration of the left eyeball was visualized with ultrasounds, suggesting an infectious process (Fig. 1 and 2).

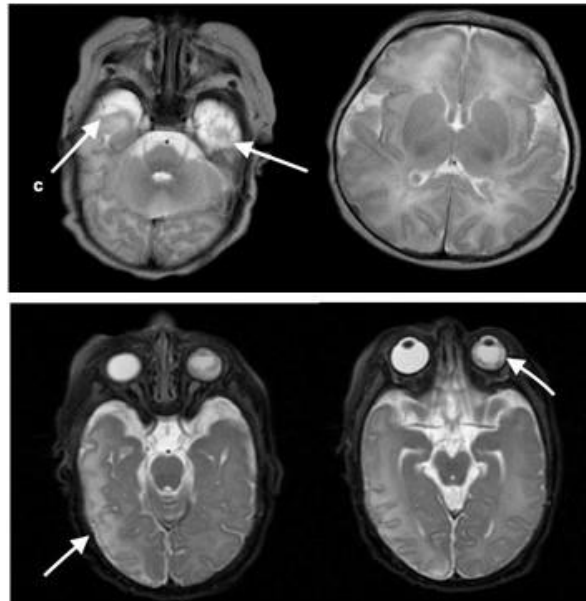


Figure 1: Brain Magnetic Resonance showing lesions consistent with evolving ischemic strokes in both frontal lobes, right temporal and occipital lobes as in the left cerebellar hemisphere

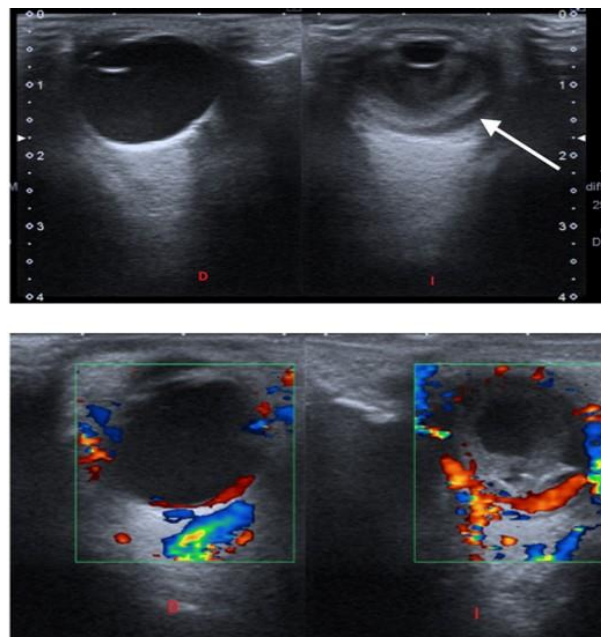


Figure 2: Orbit and optic nerve ultrasound and color doppler ultrasound for orbit and optic nerve, show alteration of the left eyeball was visualized, which suggested as infectious process

In view of the findings, an ophthalmic surgery was performed (Fig. 3 and 4) revealing crystalline synechiae and posterior chamber occupation with vitreous condensation, visualizing retinal detachment at the nasal level and panvasculitis with vascular occlusion and ischemia especially around optic nerve.

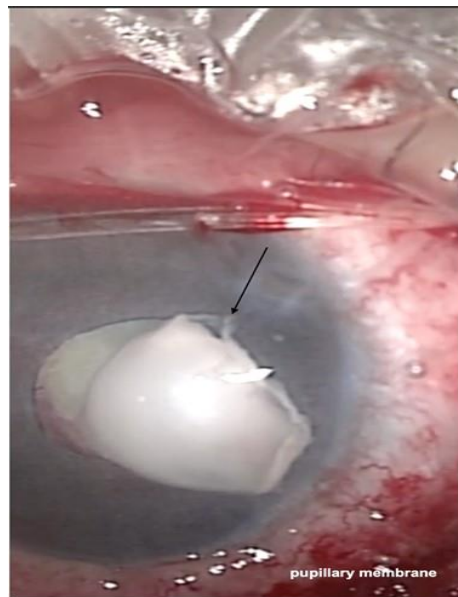


Figure 3: In view of the findings, an ophthalmic surgery was performed revealing crystalline synechia

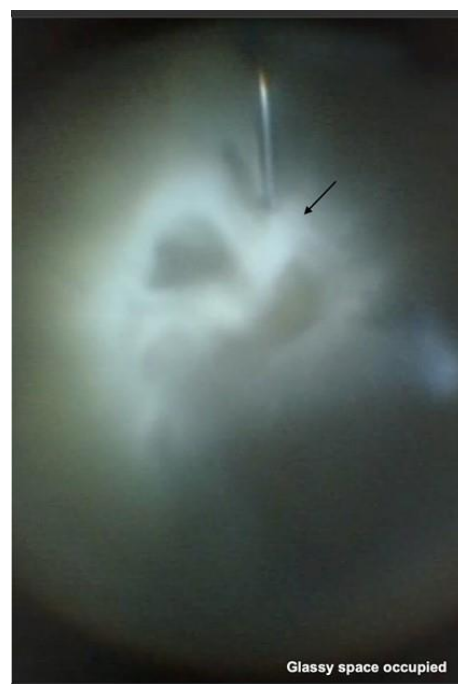

Figure 4: In view of the findings, an ophthalmic surgery was performed revealing posterior chamber occupation with vitreous condensation

Intra vitreal treatment with gentamicin was administrated and a sample of vitreous humor was collected. Serotyping performed by PCR revealed *S. pneumoniae* serotype 9.

In the immediate follow-up after the intervention, hypotonia and atrophy of the optic nerve were observed by fundus. The findings suggested that the ischemia had affected both the neuroretine and the choroid, including the ciliary bodies.

Treatment with Cefotaxime was maintained for four weeks. During admission in neonatal insensitive care unit there was a good response to the treatment with no reactivation of the source of infection or other complications.

Nine months after discharge the patient has a normal psychomotor development, but left microphthalmia and ocular ptosis. Ophthalmologist are planning a future evisceration.

Discussion and Conclusions

The most common etiologic agent of early-onset bacterial neonatal infections are group B streptococcus (GBS) and *Escherichia coli*, which are responsible for three quarters of them (Long *et al.*, 2018).

Although less common now than in the pre-antibiotic era, *Streptococcus pneumoniae* remains an important cause of neonatal sepsis. Most infants with early onset infection are ill at or within the first two days of life. Infants with late-onset sepsis due to *Streptococcus pneumoniae* usually are at term and have infection at three weeks of life or later on (Long *et al.*, 2018).

Streptococcus pneumoniae has more than 90 immunologically distinct capsular polysaccharide serotypes within 45 serogroups identified so far. Pneumococcal conjugate vaccine PCV13 contains the 7 serotypes included in the 7-valent conjugate vaccine (PCV7) (serotypes 4,6B, 9V, 14, 18C, 19F, 23F) and six additional serotypes (serotypes 1,3,5,6A,7F, 19A). Before the license of PCV7, most pneumococcal disease was caused by relatively few serotypes. With the widespread use of PCV13 the serotypes included in the vaccine have declined substantially. Newborns until six weeks of age are only protected through indirect effects (maternal antibodies) (Long *et al.*, 2018; Arfi *et al.*, 2017; Usuf *et al.*, 2018; Geelen *et al.*, 1990; Malhotra *et al.*, 2012).

Streptococcus pneumoniae colonizes the nasopharynx of healthy children and can infect the middle ear, sinuses, and lungs by contiguous spread or can invade the bloodstream and establish foci in different sites. The most important factors in the development of pneumococcal disease are the absence of type specific humoral immunity, the virulence of the serotype and the concomitant presence of viral respiratory tract disease (Long *et al.*, 2018).

Initial contact with pneumococci occurs early in life, showing a cumulative acquisition of 90% before six months of life in several studies, being a variation in the time of carriage depending on the serotypes (Fig. 5) (Long *et al.*, 2018).

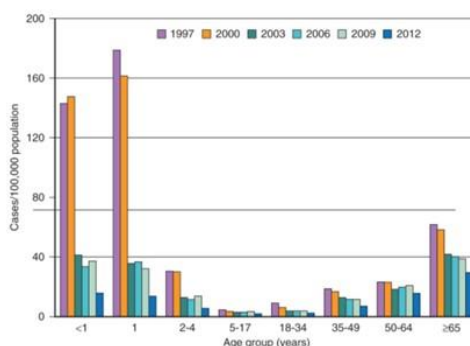


Figure 5: Rates of invasive pneumococcal disease by age group in United States in 1997, 2000, 2003, 2006, 2009, and 2012 (Long SS *et al.*, 2018)

Pneumococci are transmitted from person to person by respiratory droplets, but in neonatal infection the organism is usually acquired from the maternal genital tract (Long *et al.*, 2018). In our patient the mechanism of transmission is unknown; we cannot rule out vaginal transmission despite mother chorioamnionitis was not studied in the hospital where the delivery was performed.

Infectious endophthalmitis is an important cause of blindness. Two broad categories of infectious endophthalmitis are distinguished, exogenous and endogenous. The exogenous endophthalmitis is the most common as it is related with ocular trauma. Endogenous endophthalmitis usually occurs in a host who is already immunocompromised, but occasionally, although rarely, it can be developed in the absence of concomitant risk factors. Endocarditis and meningitis are the most important localized infections associated with endogenous endophthalmitis (Tranos *et al.*, 2016).

Gram- positive cocci are the predominant pathogens for exogenous and endogenous endophthalmitis. Endogenous bacterial endophthalmitis is responsible for less than 10% of endophthalmitis cases. Gram positive and gram negative microorganisms have been isolated in these rare cases, it can be related to neonatal group B streptococcal septicemia. *Streptococcus pneumoniae* is a very aggressive agent (Tranos *et al.*, 2016; Ng EW *et al.*, 2002; Sanders *et al.*, 2011) and unusual in newborns as cause of endophthalmitis; we have found just one publication of endophthalmitis due to *Streptococcus pneumoniae* reported in 1975 (Weinstraub and Otto, 1972).

Clinical manifestations could be just blue-grey haziness or loss of clarity in visualization of the iris and the pupil, sometimes accompanied by diminished or altered reactivity to light. It is remarkable the precocity of the clinical presentation in our patient (Long *et al.*, 2018).

Diagnosis of endogenous endophthalmitis is typically confirmed following microbiologic evidence of infection in an intraocular specimen (aqueous or vitreous), and from blood samples (Tranos *et al.*, 2016).

The key of the treatment in endogenous endophthalmitis is the use of intravenous antibiotics. The need for multiple therapeutic routes is still unclear. In this case pars plana vitrectomy for severe endophthalmitis was the only possibility to eliminate the bacterial focus and preserve the eye for a better aesthetic solution in the future (Long *et al.*, 2018; Tranos *et al.*, 2016). Especially in children and young patients, intraocular infection has a devastating outcome, although with optimal early treatment the prognosis can be better (Long *et al.*, 2018).

Our case report has several limitations. The mechanism of eye involvement is not clear, no bacteremia could be demonstrated; it is possible that endophthalmitis resulted from a contiguous foci such as meningitis. Lack of positive CSF culture for *Streptococcus pneumoniae* precludes from making an etiologic association between meningitis and endophthalmitis, however antigen test was positive in CSF. It has been validated in CSF in older children and adults, but not in newborns. *Streptococcus pneumoniae* has been detected in vitreous humor by PCR, that is highly specific and provides evidence of the etiology of endophthalmitis.

This case report highlights the importance of maintaining a high index of suspicion of eye involvement and performing the appropriate work up in cases of complicated bacterial meningitis even in early life. This case also demonstrates the utility of bacterial PCR in vitreous humor, as well as the possible role for pneumococcal antigen testing in CSF as a diagnostic tool in newborns.

List of Abbreviations

PCR: Polymerase chain reaction

CSF: Cerebrospinal fluid

NICU: Neonatal intensive care unit

GBS: Group B streptococcus

EEG: Electroencephalography

PCV: Conjugate pneumococcal vaccine

Authors' Contributions

MLR was a major contributor in writing the manuscript and did biography review, EAC was a contributor in writing the manuscript, MI was a contributor in writing the manuscript, JD was a contributor in writing the manuscript, JM was a contributor in writing the manuscript, JTR did biography review and was a contributor in writing the manuscript. All authors read and approved the final manuscript.

References

- Arfi A, Cohen R, Varon E, Béchet S, Bonacorsi S, Levy C. Case control study shows that neonatal pneumococcal meningitis cannot be distinguished from group B Streptococcus cases. *Acta Paediatr* 2017; 106: 1915-1918.
- Geelen SP, Fleer A, Bezemer AC, Gerards LJ, Rijkers GT, Verhoef J. Deficiencies in Opsonic Defense to Pneumococci in the Human Newborn Despite Adequate Levels of Complement and Specific IgG Antibodies. *Pediatr Res* 1990; 27: 514-518.
- Long SS, Prober CG, Fischer M. Principles and practice of pediatric infectious diseases E-Book. *Elsevier Health Sciences* 2018.
- Malhotra A, Hunt RW, Doherty RR. Streptococcus pneumoniae sepsis in the newborn. *J Paediatr Child Health* 2012; 48: E79-E83.
- Martínez-Chamorro MJ. Diagnóstico de laboratorio de la enfermedad neumocócica: utilidad del test rápido de detección del antígeno neumocócico en orina en Pediatría In: Grupo de Patología Infecciosa AEPap. Febrero 2014. <http://www.aepap.org/grupos/grupo-de-patologiainfecciosa/contenido>
- Ng EW, Costa JR, Samiy N, Ruoff KL, Connolly E, Cousins FV, D'Amico DJ. Contribution of pneumolysin and autolysin to the pathogenesis of experimental pneumococcal endophthalmitis. *Retina* (Philadelphia, Pa.). 2002; 22: 622-632.
- Sanders ME, Norcross EW, Robertson ZM, Moore QC, Fratkin J, Marquart ME. The Streptococcus pneumoniae capsule is required for full virulence in pneumococcal endophthalmitis. *Invest Ophthalmol Vis Sci* 2011; 52: 865-872
- Tranos P, Dervenis N, Vakalis AN, Asteriadis S, Stavrakas P, Konstas AG. Current Perspectives of Prophylaxis and Management of Acute Infective Endophthalmitis. *Adv Ther* 2016; 33: 727-746.
- Usuf E, Bojang A, Camara B, Jagne I, Oluwalana C, Bottomley C, D'Alessandro U, Roca A. Maternal Pneumococcal Nasopharyngeal Carriage and Risk Factors for Neonatal Carriage after the Introduction of Pneumococcal Conjugate Vaccines in The Gambia. *Clin Microbiol Infect* 2018; 24: 389-395.
- Weinstraub MI and Otto RN. Pneumococcal Meningitis And Endophthalmitis in a Newborn. *JAMA* 1972; 219: 1763-1764.
- Zhang M, Xu GZ, Jiang R, Ni YQ, Wang KY, Gu RP, Ding XY. Pediatric Infectious Endophthalmitis : A 271- case Retrospective Study at a Single Center in China. *Chin Med J* (Engl). 2016; 129: 2936-2943.