

Hydrocele of The Canal of Nuck in an Adult Female: A Case Report

Srikant Agrawal^{1*} | Sushil Rayamajhi² | Anu Radha Twayana³ | Pratiksha Paudel⁴

*Correspondence: Srikant Agrawal

Address: ¹MS General Surgery, Bir Hospital, National Academy of Medical Sciences, Kathmandu, Nepal; ²MBBS Graduate, Rajshahi Medical College, Rajshahi, Bangladesh; ³MBBS Graduate, Kathmandu University School of Medical Sciences, Dhulikhel, Nepal; ⁴MBBS Graduate, International Medical School, Tianjin Medical University, Tianjin, PR China

e-mail ✉: drsrikantag@gmail.com

Received: 17 June 2022; Accepted: 22 July 2022

Copyright: © 2022 Agrawal S. This is an open-access article distributed under the terms of the Creative Commons Attribution License, which permits unrestricted use, distribution, and reproduction in any medium, provided that the original work is properly cited.

ABSTRACT

In females, the round ligament connects the uterine cornu to the vulva at one end and traverses the inguinal canal at the other. The canal of Nuck is a small patent pouch of parietal peritoneum that runs along the length of this ligament. The canal of Nuck gets entirely obliterated during the first year of life, and the inability to do so might result in a hydrocele or an inguinal hernia. Hydrocele of the canal of the Nuck is difficult to diagnose because the diagnosis is rarely made solely on the basis of clinical signs. However, the results of a preoperative USG might be helpful. The information and knowledge regarding hydrocele of the canal of Nuck is limited, so this case report will benefit the existing literature.

Keywords: Hydrocele of the Canal of Nuck, Round ligament, Inguinal Swelling

Introduction

The male spermatic cord and the female's round ligament of the uterus both pass via the inguinal canal. In inguinal canal of females, a small patent pouch of parietal peritoneum, known as the 'canal of Nuck', is accompanied by the round ligament. It is equivalent to the processus vaginalis in males (Sarkar *et al.*, 2016). It was first described by dutch anatomist, Anton Nuck in 1691 (Tubbs *et al.*, 2007). Within first year, the canal of Nuck typically loses connection with the peritoneal cavity, but if it fails, it can cause a hernia or hydrocele (Kono *et al.*, 2015). Partial obliteration of the peritoneal pouch results in the canal of Nuck hydrocele, a relatively uncommon disease in women. In comparison to prior accounts, this entity is now thought to be more widespread; yet, it remains an unfamiliar concern for clinicians (Sarkar *et al.*, 2016).

It is most commonly seen in children, and it is quite rare in adults. Due to the small number of cases recorded, information on the incidence and presentation in adults is restricted. As a result, in a clinical setting like the one described above, a differential diagnosis of hydrocele of the canal of Nuck of a groin swelling in an adult female would be advantageous (Patnam *et al.*, 2016).

We discuss a rare case of such developmental disorder in an adult female since it is rarely seen in surgical practice. The aim of this study is to discuss the clinical picture, radiological notes, histological findings, differential diagnosis, and surgical treatment of this illness in light of our experience because it's crucial to distinguish it from other clinical mimics.

Case Report

A 46-year-old lady presented with a palpable right inguinal swelling with occasional pain. She first noticed a slight swelling measuring about 2 cm * 2 cm in the right inguinal region 4 years back, which gradually enlarged to become the present size of about 4 cm * 3 cm. The mass was not noticed in infancy or adolescence. Prior to her presentation, the painless bulge had persisted for 1 year. Pain in her right groin for the last 1 month prompted her to seek medical attention. There was no history of trauma, redness, or related skin edema. Her menstrual history was unremarkable.

On local examination, an irreducible, fluctuant swelling measuring 4 cm * 3 cm was present in right inguinal region. Cough impulse was absent, and the overlying skin was normal. The swelling didn't transilluminate. Despite the lesion being irreducible, neither incarceration nor strangulation was seen. The mass demonstrated positive fluctuation. Neither peristaltic activity nor abnormal vascularity associated with the swelling was seen. Signs of inflammation were absent. The patient's vital signs were normal. Laboratory parameters were within normal limits. Right inguinal region ultrasonography showed hypoechoic swelling with thin internal septations and no communication with the peritoneal cavity.

The patient was transferred to the operation theater. A right inguinal exploration was performed with a transverse skin incision, where a cystic lesion of size 6*4 cm was discovered after cutting the skin, subcutaneous tissue and external oblique aponeurosis. It was immediately recognized to be an encysted hydrocele of the canal of Nuck ([Fig. 1](#) and [2](#)). The hydrocele of the canal of Nuck was carefully separated from the round ligament, excised and sent for histopathological examination. The deep inguinal ring was ligated to confirm there was no herniation. The external oblique aponeurosis, subcutaneous tissue and skin were closed in layers.

The postoperative period was uneventful, and she was discharged after 7 days. The recovery was satisfactory. Pathological examination confirmed that the specimen was a hydrocele of the canal of Nuck, microscopic findings of the cyst showing chiefly fibrovascular tissue with a single layer of mesothelial cells on the inner surface. On follow-up after 2 weeks and again at 2 months, there were no complaints from the patient.

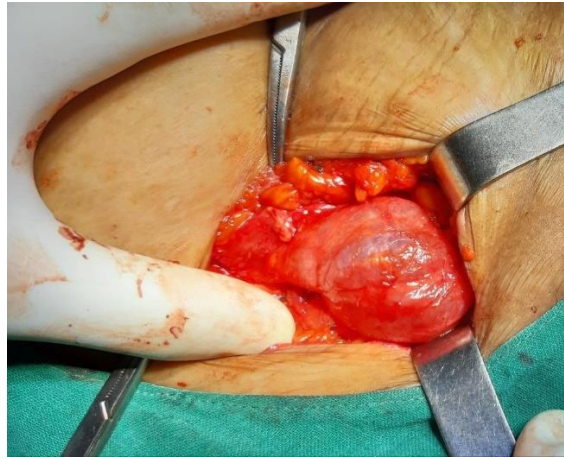


Figure 1: Intraoperative photograph. A cyst can be seen in the canal of Nuck.

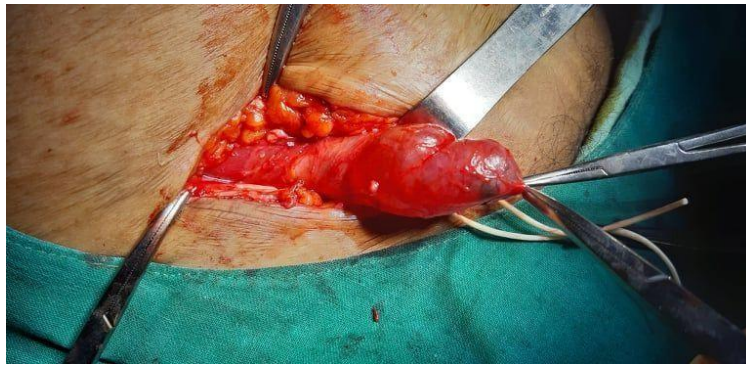


Figure 2: Surgical exploration; Intraoperative view of well-circumscribed and non-communicated nuck canal cyst.

Discussion

The Canal of Nuck is a small patent pouch of the parietal peritoneum that occurs during the first year of female development as the round ligament enters the inguinal canal (Patnam *et al.*, 2016). The round ligament follows the processus vaginalis into the inguinal canal and into the labium majus. The canal of Nuck in the female is the evagination of the parietal peritoneum (Kono *et al.*, 2015). The incidence of the hydrocele of the canal of Nuck in female child was 1% (Huang *et al.*, 2013). Only 0.76% of girls less than 12 years exhibited hydrocele of canal of the Nuck among their study population (Akkoyun *et al.*, 2013). During the first year, this peritoneal evagination usually disappears completely. The inability of the processus vaginalis to close may lead to the development a hydrocele or hernia (Kono *et al.*, 2015). The causes are generally idiopathic, although they can also be linked to inflammation, trauma, or a lack of lymphatic drainage (Patnam *et al.*, 2016). The incidence in adult females is unclear because of the rarity though few case reports have been reported (Sarkar *et al.*, 2016).

Most of the current studies show that hydrocele of the canal of Nuck presents clinically as a transparent, painless, or moderately tender fluctuant inguinal mass without associated nausea or

vomiting, making it difficult to diagnose this entity only on the basis of clinical signs. These masses are irreducible and, if large enough, can transilluminate (Kono *et al.*, 2015). Similar to these studies, the female we are reporting came with the complaint of a palpable mass in the right inguinal region with occasional pain. Since the external oblique muscle fascia covers all hydrocele, it may not be easily seen (Patnam *et al.*, 2016). However, in our case, the patient had a small-sized swelling in the right inguinal region 4 years back, which gradually enlarged to become the present size.

Hydrocele of canal of the Nuck is an accumulation of fluid within the vaginal canal in females, which is a very uncommon occurrence (Kono *et al.*, 2015). In the hernial sac, peritoneal fluid, bowel loops, omental fat, fallopian tube, ovary and urinary bladder can all be found. As a result, surgeons can use preoperative imaging to prevent inflicting injury while analyzing the anatomical region around the inguinal canal (Kim *et al.*, 2016). Ultrasonography is frequently used inexpensive and accurate method to image inguinal lesions for the first time (Kono *et al.*, 2015). It appears as a well-defined, anechoic or hypoechoic, unilocular or multilocular cystic structure. Inguinal hernias on the other hand appear hyperechoic. MRI gives the perfect diagnosis and may be utilized as an imaging tool as well as a tool for determining the severity of the hydrocele (Kono *et al.*, 2015). If ultrasonography and CECT can confirm the diagnosis, MRI may be avoided since it is more costly than the other two. Only after surgery may a definitive diagnosis be made and verified by pathological testing (Patnam *et al.*, 2016). In our case, ultrasonography of the right inguinal region was done which revealed hypoechoic swelling with thin internal septations and it did not communicate with the peritoneal cavity. There was no associated herniation of internal organs. Further investigation with MRI or CECT was not done in our case.

Hydrocele of canal of Nuck has been pathologically associated with fertility. Ovary herniation or endometriosis of the canal may lead to infertility in young females (Choi and Baek, 2016). Unfortunately, none of the reported cases had any information on postoperative fertility.

The canal of Nuck hydrocele should be treated by surgical removal of the cyst without puncturing it in adults. Studies suggest surgical excision with ligation of the sac as the standard choice of treatment. The aspiration of canal of Nuck hydrocele is insufficient, resulting in a high rate of recurrence (Kono *et al.*, 2015; Patnam *et al.*, 2016). An additional vulva correction may be required in cases of mass extension to labia majora (Ferreira *et al.*, 2017). Similar to the studies, ligation near the deep inguinal ring was performed in our patient, confirming there was no herniation. Complications related to the canal of Nuck hydrocele include infection or rupture (Ameh and Garba, 2003).

Although the canal of Nuck hydrocele is now thought to be more prevalent than previously thought; it is still a new concern for doctors, and some cases are misdiagnosed as incarcerated and

strangulated inguinal hernias, enlarged lymph nodes, lipomas, leiomyomas, cold abscess, endometriosis of round ligament before surgery (Kono *et al.*, 2015; Patnam *et al.*, 2016). In addition, because numerous differential diagnoses for inguinal swelling in females are given, it is critical for physicians, particularly surgeons and radiologists, to recognize and grasp this phenomenon appropriately (Kono *et al.*, 2015).

Conclusion

A differential of canal of Nuck hydrocele should be considered in an adult female with painless, irreducible, and fluctuant groin swelling. Although it is an uncommon ailment, its similarities to other illnesses make the diagnosis challenging. A precise diagnosis may not be achievable based on physical examination; thus, preoperative evaluation using imaging will be beneficial. Complete surgical excision is the preferred therapy.

Declarations

Ethics Approval and Consent to Participate: Not applicable.

Consent to Publish: Written informed consent was taken from the patient and patient party for publication of this report.

Availability of Data and Materials: Secondary data were collected from the patient's hospital records.

Competing Interests: The authors have no competing interest for the publication of this case report.

References

Akkoyun I, Kucukosmanoglu I, Yalinkilinc E. Cyst of the canal of nuck in pediatric patients. *N Am J Med Sci* 2013; 5: 353–356.

Ameh EA and Garba ES. Infected hydrocoele of the canal of Nuck in a neonate. *Urol Int* 2003; 71: 226–227.

Choi KH and Baek HJ. Incarcerated ovarian herniation of the canal of Nuck in a female infant: Ultrasonographic findings and review of literature. *Ann Med Surg (Lond)* 2016; 9: 38–40.

Ferreira AF, Marques JP, Falcao F. Hydrocele of the canal of Nuck presenting as a sausage-shaped mass. *BMJ Case Rep* 2017; pp: bcr-2017.

Huang CS, Luo CC, Chao HC, Chu SM, Yu YJ, Yen JB. The presentation of asymptomatic palpable movable mass in female inguinal hernia. *Eur J Pediatr* 2003; 162: 493–495.

Kim KS, Choi JH, Kim H, Kim KP, Kwon YJ, Hwang JH, Lee SY. Hydrocele of the Canal of Nuck in a Female Adult. *Arch Plast Surg* 2016, 43: 476–478.

Kono R, Terasaki H, Murakami N, Tanaka M, Takeda J, Abe T, (2015), Hydrocele of the canal of Nuck: A case report with magnetic resonance hydrography findings. *Surg Case Rep* 2015; 1: 86.

Patnam V, Narayanan R, Kudva A, A cautionary approach to adult female groin swelling: Hydrocoele of the canal of Nuck with a review of the literature. *BMJ Case Rep* 2016; 2016: bcr2015212547.

Sarkar S, Panja S, Kumar S, Hydrocele of the Canal of Nuck (Female Hydrocele): A Rare Differential for Inguino-Labial Swelling. *J Clin Diagn Res* 2016; 10: 21–22.

Tubbs RS, Loukas M, Shoja MM, Salter EG, Oakes WJ. Indirect inguinal hernia of the urinary bladder through a persistent canal of Nuck: Case report. *Hernia* 2007; 11: 287–288.