

Complications in Testing for COVID-19 with Nasopharyngeal Swabs: The Severance of a Nasopharyngeal Swab in a 13-Month-Old Toddler and Review of Literature

Lea Kahlenberg* | Juliane Krüger | Dominik Lwowsky | Christoph Fusch*

*Correspondence: Lea Kahlenberg and Christoph Fusch

Address: Department of Pediatrics, Paracelsus Medical University, Nuremberg General Hospital, Germany

e-mail ✉: Lea.kahlenberg@klinikum-nuernberg.de; Christoph.fusch@klinikum-nuernberg.de

Received: 01 March 2022; Accepted: 14 March 2022

Copyright: © 2022 Kahlenberg L. This is an open-access article distributed under the terms of the Creative Commons Attribution License, which permits unrestricted use, distribution, and reproduction in any medium, provided that the original work is properly cited.

ABSTRACT

Since the beginning of the COVID-19 pandemic, the number of nasopharyngeal smears increased enormously to detect SARS-CoV-2 and consequently break the chain of infection. Yet, only a few cases of complications during the collection of smears are reported. This case report describes the treatment of a toddler who presented in our pediatric emergency ward with a broken swab after nasopharyngeal COVID-19 testing and the currently unknown location of the swab in the body. Subsequently, other complications in testing for COVID-19 are reviewed though no comparable case has been published so far in the pediatric field. Concluding methods to prevent and treat complications are discussed.

Keywords: COVID-19, Complication, Pediatrics, Nasopharyngeal Swab

Introduction

Since the beginning of the COVID-19 pandemic, PCR and antigen testing for SARS-CoV-2 is important for tackling the pandemic. (RKI, 2021a) Especially because of possible asymptomatic or mild and unspecific courses of the disease (RKI, 2021b), tests help to detect infections and subsequently break the chain of infection (RKI, 2021a). The gold standard for diagnosing SARS-CoV-2 is defined as a nasopharyngeal swab for PCR testing (RKI, 2021a). Despite vaccination coverage of 70% of the total population in Germany (as of December 16th, 2021), it is only 49.5% in the age group from 12 to 17 years of age (RKI, 2021c). One reason for this is the general vaccination recommendation for children and adolescents between the ages of 12 and 17 that was authorized by the German permanent vaccination commission (STIKO) on August 16th, 2021 (RKI, 2021d). In addition, there is no vaccination recommendation for children aged five to 11 years that has been announced on December 9th, 2021 despite children having comorbidities (RKI, 2021e). Vaccinations for children under five years have not yet been approved in the EU. Thus, in the age groups up to 18 years of age testing for SARS-CoV-2 will still be necessary to contain pandemics during the fourth wave in Germany and with the appearance of

Omicron. Additionally, also vaccinated persons could transmit the virus and therefore need to be tested for SARS-CoV-2 to break the chain of infections.

In our pediatric department, all newly admitted children are screened for SARS-CoV-2 using both PCR and antigen tests. As the number of nasopharyngeal and oropharyngeal smears increases, so do the number of associated complications. An example of a complication is the following case report, in which a swab broke during the swabbing procedure in the nasopharynx of a 13-month-old toddler performed by a local pediatrician. As a result, the toddler receives a nasal endoscopy with pharyngoscopy, a bronchoscopy, and an esophagogastroduodenoscopy with a total of three sedations to localize and eventually successfully remove the foreign body.

Case Report

Anamnesis

A 13-month-old male toddler presented in the pediatric emergency ward with a broken swab after deep nasal COVID-19 testing and a currently unknown location of the swab in the body.

Previously, he had been presented to the local pediatrician because of fever for two days, as well as rhinitis and a mild cough. The local pediatrician found the patient in good general condition with the infection already subsiding and only subfebrile temperatures. A COVID-19 antigen rapid test had to be carried out to approve the visit to the daycare center in the following week. The deep nasal swab was carried out during which the swab broke off at the predetermined breaking point. The child then coughed and choked. The pediatrician was able to localize the swab briefly on the back of the pharynx immediately after it broke off. However, it was no longer visible there until a Magill forceps was provided to retrieve the swab. Due to the last visualization of the location in the nasopharynx, the patient was initially presented to the ENT emergency room.

A nasal endoscopy followed by a pharyngoscopy in sedation was carried out. Both examinations were performed without complications. However, the foreign body was neither located nor recovered, so the child was sent to our pediatric emergency ward for further diagnostics.

Admission and Laboratory Findings:

The physical examination showed inspiratory stridor in an otherwise stable respiratory situation. According to the mother, this stridor occurred for the first time on their way to the pediatric emergency room. In addition, the pharyngeal mucous membrane was reddened and swollen. Slightly increased inflammation values were interpreted as the subsiding infection of the upper airways. The COVID-19 PCR

test carried out on admission was negative.

Vital signs upon admission: temperature: 37.4°C, heart rate: 118/minute, oxygen saturation: 98%, breathing rate: 32/minute.

Therapy and Progress

Due to the newly developed stridor, foreign body aspiration was suspected. Due to non-radiopaque material and symmetrical noises, an x-ray was not performed. Instead, a bronchoscopy was performed under general anesthesia, during which however no foreign body was found.

As the swab was neither detected in the upper nor the lower airways, an esophagogastroduodenoscopy was performed next. The approximately 10 cm long foreign body could be recovered as a whole without further complications from the stomach.

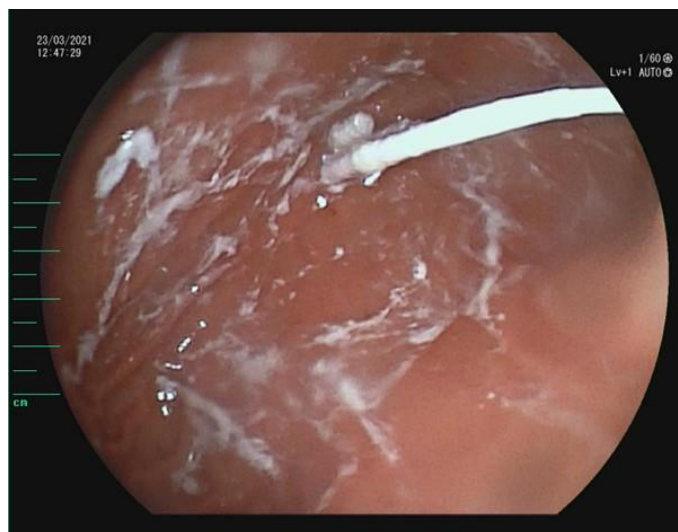

Figure 1: Swab found in the stomach. The picture was taken during esophagogastroduodenoscopy.




Figure 2: Removed swab from the stomach. The swab could be recovered as a whole.

After 24 hours of monitoring and with improving stridor, the patient was discharged.

Discussion

Despite the pandemic-related increase in nasopharyngeal smears, only a few cases of complications during the collection of smears have been documented. In addition to epistaxis, retained swab tips, and cerebrospinal fluid leaks, case reports of prematurely broken swabs have been described (Mughal *et al.*, 2020). In the pediatric field, no comparable case has been published to date.

A risk factor for prematurely broken swabs appears to be poor patient compliance. Literature shows that defensive movements favored breaking off the swab during the smear procedure in previously neurologically ill (Hussain *et al.*, 2020; Mughal *et al.*, 2020), vigilance-reduced (Stevens *et al.*, 2021), and mentally disabled (Gaffuri *et al.*, 2021) patients, but it is also plausible in the pediatric field.

In our case report, however, no jerky movement was observed that would encourage the swab to break off. This also seems to be the case in adults in three further case reports Feld (Azar *et al.*, 2020; De Luca and Maltoni, 2021; Hussein *et al.*, 2020). The nature of the swab with the predetermined breaking point seems to represent an increased risk of premature severance but increases the work safety of the employees when the swab is further processed.

In the case reports of prematurely broken swabs, the foreign material was aspirated in two cases, both of which were tracheostoma patients from whose tracheostomy the swab was taken (Hussain *et al.*, 2020; Hussein *et al.*, 2020). In three other case reports, the swab was located in the nasal cavity (Azar *et al.*, 2020; Gaffuri *et al.*, 2021; Mughal *et al.*, 2020). The broken swab was ingested in two case reports and subsequently excreted via naturalis in one case report (Stevens *et al.*, 2021), and removed by endoscopy in the second one (De Luca and Maltoni, 2021). Both patients were asymptomatic concerning the ingestion of the swab (De Luca and Maltoni, 2021; Stevens *et al.*, 2021). The 13-month-old toddler developed inspiratory stridor with stable vital signs caused by the irritation of the mucous membrane and consequent swelling due to the ingestion of the swab. That is why initially a misinterpretation regarding suspected aspiration was conducted.

Radiopaque marking of the swab or swabs made of radiopaque material could have helped to localize the foreign material and to carry out fewer interventions and associated sedations. However, a case report has also been published in which the swab was made of aluminum and, despite the radiopaque material, could not be detected radiologically by x-rays (Azar *et al.*, 2020). Publications on aluminum-containing foreign bodies, for example beverage can pull tabs (Donnelly, 2010; Egli *et al.*, 1986; Kotsenas *et al.*, 2014; Stewart *et al.*, 1994), coins (Takahashi *et al.*, 2017), or ammunition (Conradi, 1982) show that the material can easily be detected in soft tissue, but detection is significantly more

difficult when an x-ray cannot be carried out without bones overlaying the imaging (Ellis, 1993; Valente et al., 2005). Kotsenas, et al. (2014) and Tseng, et al. (2015) see CT scanning as the method of choice for the detection of aluminum-containing foreign bodies, but this is controversial in pediatrics due to the high radiation exposure.

Conclusion

According to the Robert Koch Institute (German Society for Hygiene and Microbiology), a total of 87,852,398 tests were transmitted in 2021 up to calendar week 48 (RKI, 2021f). The low number of documented complications shows the relatively low risk of taking the smear. The documented complications that were found in the literature are shown in Table 1.

The correct execution of the swab collection and the correct positioning of the patient play an important role, especially in patients with reduced compliance, to avoid complications. Overall, the benefits of COVID-19 diagnostics outweigh the risks of nasopharyngeal and oropharyngeal swabs. The PCR and antigen tests for SARS-CoV-2 are important tools to fight against the pandemic. This is especially true for the age group 0 to 11 years, for whom vaccination has not yet been approved or general vaccination recommendation has not been formulated and in which we see a significant increase in the number of infected persons (RKI, 2021g).

Table 1: Complications of nasopharyngeal smears.

| Complications | Number of case reports | Sources |
|--|------------------------|--|
| Fractured nasal swabs during collection | 14 | Azar et al., 2020; De Luca and Maltoni, 2021; Gaffuri et al., 2021; Hussain et al., 2020; Hussein et al., 2020; Koskinen et al., 2021; Medas et al., 2020; Mughal et al., 2020; Stevens et al., 2021; Suresh, 2021; Wyman et al., 2021 |
| Retained swab tips | 5 | Fabbris et al., 2021; Föh et al., 2021 |
| Nasal septal abscess | 1 | Fabbris et al., 2021 |
| Temporomandibular joint dislocation | 1 | Föh et al., 2021 |
| Epistaxis | 20 | Fabbris et al., 2021; Gupta et al., 2021; Koskinen et al., 2021 |
| Skull base complications with cerebrospinal fluid leak | 5 | Alberola-Amores et al., 2021; Mistry et al., 2021; Paquin et al., 2021; Rajah and Lee, 2021; Sullivan et al., 2020 |

References

- Alberola-Amores FJ, Valdeolivas-Urbelz E, Torregrosa-Ortiz M, Álvarez-Sauco M, Alom-Poveda J. Meningitis due to cerebrospinal fluid leak after nasal swab testing for COVID-19. *Eur J Neurol* 2021; 28: e91–e92.
- Azar A, Wessell DE, Janus JR, Simon LV. Fractured aluminum nasopharyngeal swab during drive-through testing for COVID-19: radiographic detection of a retained foreign body. *Skeletal Radiol* 2020; 49: 1873-1877.
- Conradi SE. New aluminum-jacketed ammunition: the case of the "invisible" jacket. *Am J Forensic Med Pathol* 1982; 3: 153-155.
- De Luca L and Maltoni S. Is naso-pharyngeal swab always safe for SARS-CoV-2 testing? An unusual, accidental foreign body swallowing. *Clin J Gastroenterol* 2021; 14: 44-47.
- Donnelly LF. Beverage can stay-tabs: still a source for inadvertently ingested foreign bodies in children. *Pediatr Radiol* 2010; 40: 1485-1489.
- Eggl KD, Potter BM, Garcia V, Altman RP, Breckbill DL. Delayed diagnosis of esophageal perforation by aluminum foreign bodies. *Pediatr Radiol* 1986; 16: 511-513.
- Ellis GL. Are aluminum foreign bodies detectable radiographically? *Am J Emerg Med* 1993; 11: 12-13.
- Fabbris C, Cestaro W, Menegaldo A, Spinato G, Frezza D, Vijendren A, Borsetto D, Boscolo-Rizzo P. Is oro/nasopharyngeal swab for SARS-CoV-2 detection a safe procedure? Complications observed among a case series of 4876 consecutive swabs. *Am J Otolaryngol* 2021; 42: 102758.
- Föh B, Borsche M, Balck A, Taube S, Rupp J, Klein C, Katalinic A. Complications of nasal and pharyngeal swabs: a relevant challenge of the COVID-19 pandemic? *Eur Respir J* 2021; 57.
- Gaffuri M, Capaccio P, Torretta S, Daga M, Zuccotti GV, Pignataro L. An unusual retained choanal foreign body: a possible complication of COVID-19 testing with nasopharyngeal swab. *Ear Nose Throat J* 2021; 1: 0145561321993933.
- Gupta K, Bellino PM, Charness ME. Adverse effects of nasopharyngeal swabs: Three-dimensional printed versus commercial swabs. *Infect Control Hosp Epidemiol* 2021; 42: 641-642.
- Hussain MH, Siddiqui S, Mahmood S, Valsamakis T. Tracheal swab from front of neck airway for SARS-CoV-2; a bronchial foreign body. *BMJ Case Rep* 2020; 13: e237787.
- Hussein MS, Hameed M, Allangawi M, Abdelsattar H, Haq IU. An unusual and unexpected result of diagnostic sampling for COVID-19. *Cureus* 2020; 12.
- Koskinen A, Tolvi M, Jauhiainen M, Kekäläinen E, Laulajainen-Hongisto A, Lamminmäki S. Complications of COVID-19 nasopharyngeal swab test. *JAMA Otolaryngol Head Neck Surg* 2021; 147: 672-674.
- Kotsenas AL, Campeau NG, Oeckler RA, Kuzo RS. Evaluation of suspected aspirated beverage can pull tab: radiographs may not be enough. *Case Rep Radiol* 2014; 2014: 196960.
- Medas R, Coelho R, Macedo G. An unusual collateral damage of COVID-19 pandemic. *Gastrointest Endosc* 2020; 92: 1261-1262.
- Mistry SG, Walker W, Earnshaw J, Cervin A. COVID-19 swab-related skull base injury. *Med J Aust* 2021; 214: 457-459.
- Mughal Z, Luff E, Okonkwo O, Hall CE. Test, test, test—a complication of testing for coronavirus disease 2019 with nasal swabs. *J Laryngol Otol* 2020; 134: 646-649.

Paquin R, Ryan L, Vale FL, Rutkowski M, Byrd JK. CSF leak after COVID-19 nasopharyngeal swab: a case report. *The Laryngoscope* 2021; 131: 1927-1929.

Rajah J and Lee J. CSF rhinorrhoea post COVID-19 swab: a case report and review of literature. *J Clin Neurosci Off J Neurosurg Soc Australas* 2021; 86: 6-9.

Stevens MN, Lin GT, Tittman SM, Motz KM. SARS-CoV-2 nasopharyngeal swab as a foreign body: a case report. *Ear Nose Throat J* 2021; p:0145561321996836.

Stewart GD, Lakshmi MV, Jackson A. Aluminium ring pulls: an invisible foreign body. *J Accid Emerg Med* 1994; 11: 201-203.

Sullivan CB, Schwalje AT, Jensen M, Li L, Dlouhy BJ, Greenlee JD, Walsh JE. Cerebrospinal fluid leak after nasal swab testing for coronavirus disease 2019. *JAMA Otolaryngol Head Neck Surg* 2020; 146: 1179-1181.

Suresh V. Anesthesia for extraction of a fractured COVID-19 nasopharyngeal swab. *Int J Pediatr Otorhinolaryngol* 2021; 143: 110611.

Takahashi J, Shiga T, Funakoshi H. Oesophageal coins invisible on chest radiography: a case report. *Int J Emerg Med* 2017; 10: 1-3.

Tseng HJ, Hanna TN, Shuaib W, Aized M, Khosa F, Linnau KF. Imaging foreign bodies: ingested, aspirated, and inserted. *Ann Emerg Med* 2015; 66: 570-582.

Valente JH, Lemke T, Ridlen M, Ritter D, Clyne B, Reinert SE. Aluminum foreign bodies: do they show up on x-ray? *Emerg Radiol* 2005; 12: 30-33.

Wyman MT, Symms J, Viscusi C. Nasal foreign body, an unanticipated complication of COVID-19 Care: a case report. *J Emerg Med* 2021; 60: e141-e145.

Web Links

RKI, 2021a. Hinweise zur Testung von Patienten auf Infektion mit dem neuartigen Coronavirus SARS-CoV-2, Stand: 12.5.2021 [WWW Document]. URL https://www.rki.de/DE/Content/InfAZ/N/Neuartiges_Coronavirus/Vorl_Testung_nCoV.html;jsessionid=2A5734231ADA14D34F41467EB8635E4F.internet081?nn=13490888 (accessed 5.30.21).

RKI, 2021b. Epidemiologischer Steckbrief zu SARS-CoV-2 und COVID-19, Stand: 19.4.2021 [WWW Document]. URL https://www.rki.de/DE/Content/InfAZ/N/Neuartiges_Coronavirus/Steckbrief.html;jsessionid=86D58FC5E1CFB550507E50761FABE447.internet051?nn=13490888#m (accessed 5.30.21).

RKI, 2021c. Tabelle mit den gemeldeten Impfungen nach Bundesländern und Impfquoten nach Altersgruppen (16.12.2021) [WWW Document]. URL https://www.rki.de/DE/Content/InfAZ/N/Neuartiges_Coronavirus/Daten/Impfquotenmonitoring.xlsx?_blob=publicationFile (accessed 12.16.21).

RKI, 2021d. Mitteilung der STIKO zur Aktualisierung der COVID-19-Impfempfehlung für Kinder und Jugendliche (16.8.2021) [WWW Document]. URL https://www.rki.de/DE/Content/Kommissionen/STIKO/Empfehlungen/PM_2021-08-16.html (accessed 9.9.21).

RKI, 2021e. Pressemitteilung der STIKO zur COVID-19-Impfempfehlung für Kinder im Alter von 5 bis 11 Jahren (9.12.2021) [WWW Document]. URL https://www.rki.de/DE/Content/Kommissionen/STIKO/Empfehlungen/PM_2021-12-09.html (accessed 12.16.21).

RKI, 2021f. Tabellen zu Testzahlen, Testkapazitäten und Probenrückstau pro Woche (9.12.2021) [WWW Document]. URL https://www.rki.de/DE/Content/InfAZ/N/Neuartiges_Coronavirus/Daten/Testzahlen-gesamt.xlsx?__blob=publicationFile (accessed 12.16.21).

RKI, 2021g. Covid-19-Trends in Deutschland im Überblick, Stand 02.09.2021 [WWW Document]. URL https://www.rki.de/DE/Content/InfAZ/N/Neuartiges_Coronavirus/Situationsberichte/COVID-19-Trends/COVID-19-Trends.html?__blob=publicationFile#/home (accessed 9.9.21).