

A Rare Case of Pulmonary Renal Syndrome Secondary to Microscopic Polyangiitis – A Case Report

Viraj Shah^{1*} | Alexandra Lacqua² | Gregory Demirjian^{4,3} | Akash Patel⁴ | Dhruvil Shah⁵ | Taaha Mendha⁶

*Correspondence: Viraj Shah

Address: ¹The Florida Atlantic University, Internal Medicine Residency Program; Boca Raton, Florida; ²The Florida Atlantic University, Internal Medicine Residency Program; Boca Raton, Florida; ³Charles E. Schmidt College of Medicine; Boca Raton, Florida; ⁴Pramukhswami Medical College, Karamsad, India; ⁵Texila American University, Guyana; ⁶The Florida Atlantic University, Internal Medicine Residency Program; Boca Raton, Florida

e-mail ✉: vshah@health.fau.edu

Received: 20 January 2022; Accepted: 25 January 2022

Copyright: © 2022 Shah V. This is an open-access article distributed under the terms of the Creative Commons Attribution License, which permits unrestricted use, distribution, and reproduction in any medium, provided that the original work is properly cited.

ABSTRACT

Diffuse Alveolar Hemorrhage (DAH) is one of the life-threatening pulmonary complications of AAV (ANCA-Associated Vasculitis). Pulmonary Renal Syndrome (PRS) is defined as concurrent autoimmune-induced DAH and Rapidly progressive glomerulonephritis (RPGN). Major organs involved in MPA (Microscopic Polyangiitis) are the kidneys and the lungs. The gold standard to confirm alveolar hemorrhage is bronchoalveolar lavage (BAL). We hereby describe a case in which our patient presented to the emergency room after being sent by his nephrologist for kidney biopsy in the setting of unexplained worsening renal functions. Patient ultimately developed PRS and was started on remission treatment with pulse dose steroids, plasmapheresis, and cyclophosphamide. Unfortunately, the patient deceased from multiorgan failure secondary to septic shock. PRS, once suspected, appropriate autoimmune workup should be undertaken, usually followed by renal biopsy.

Keywords: AAV (ANCA-Associated Vasculitis), (PRS) Pulmonary Renal Syndrome

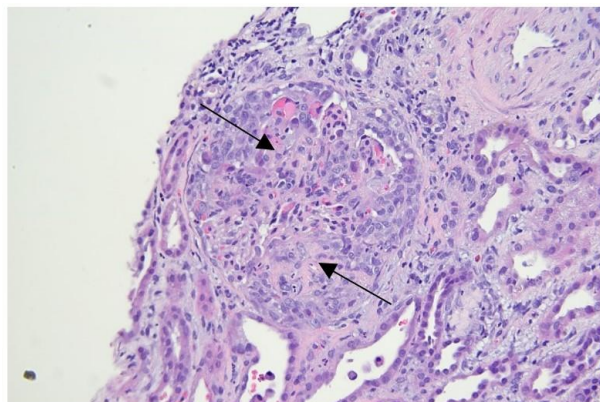
Introduction

AAV (ANCA-Associated Vasculitis) is a heterogeneous group of systemic autoimmune diseases characterized by small-vessel necrotizing vasculitis with multisystem involvement (Villiger PM and Guillevin, 2010). Granulomatosis with polyangiitis (GPA), microscopic polyangiitis (MPA), and eosinophilic granulomatosis with polyangiitis (EGPA) are the three main types of AAV. Lung involvement in the AAV is very common and is associated with increased mortality (Sacoto *et al.*, 2020). Pulmonary vasculitis is characterized by inflammation and necrosis of the pulmonary blood vessels. Pulmonary hemorrhage (PH) is a potentially life-threatening manifestation of AAV (Greco *et al.*, 2015).

Case Description

A 49-year-old male patient with history of hypertension was sent by his nephrologist to the emergency room for unexplained worsening renal function and likely renal biopsy. Vital signs were stable, physical exam was unremarkable, however BUN was 85 mg/dL with creatinine of 10.1 mg/dL (baseline of 1.5 mg/dL). Urine analysis (UA) revealed microscopic hematuria with 2+ protein and RBC casts. 24-hour urine protein excretion was 5.2 grams. The patient was started on pulse dose methylprednisolone for a total of 3 days (West *et al.*, 2013). CT scan (Computed Tomography) of chest showed ground-glass opacities and interstitial thickening more pronounced at the bases. Rheumatologic workup was significant for p-ANCA with Myeloperoxidase antibody (MPO) of 134 AU/mL (normal <26), negative Anti-PR3 and Anti-GBM and normal C3 and C4 levels. Renal biopsy revealed active pauci-immune crescentic and necrotizing glomerulonephritis with fibrinoid necrosis involving an artery consistent with rapidly progressive glomerulonephritis (RPGN) as shown in Fig. 1. A diagnosis of microscopic polyangiitis (MPA) was made.

The patient progressively became encephalopathic and had an episode of massive hemoptysis of 400 cc frank blood. Subsequently, the patient was intubated and started on hemodialysis. Nebulized tranexamic acid (TXA) and protamine sulfate were used to stop hemoptysis. Bronchoscopy with bronchoalveolar lavage (BAL) revealed blood with increasingly hemorrhagic appearance of consecutive BAL aliquots consistent with Diffuse Alveolar Hemorrhage (DAH). The patient was then reduced to methylprednisolone 60 mg IV every 6 hours, and rituximab, cyclophosphamide, and plasmapheresis were initiated (McCabe *et al.*, 2011). On day 15, the patient was extubated and did not require further dialysis. However, shortly thereafter, the patient became hypotensive and developed septic shock secondary to pneumonia and had to be intubated again. The patient was started on vasopressors, broad spectrum antibiotics and supportive management. Unfortunately, the patient developed multiorgan failure and had cardiac arrest on day 20 and deceased despite aggressive resuscitative efforts.



A

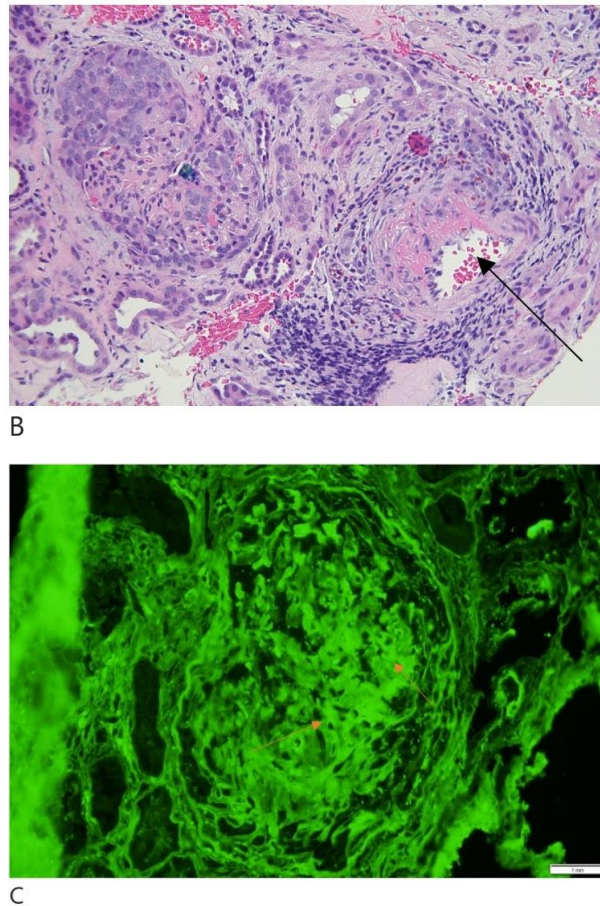


Figure 1: Renal biopsy showing glomeruli with active cellular crescents and necrotizing lesions (A). Fibrinoid necrosis in a vessel wall pointed by the arrow (B). Immunofluorescence staining fibrinogen in crescent (C).

Discussion

Pulmonary involvement in AAV can present as necrotizing granulomatous inflammation, tracheobronchial inflammation, pulmonary capillaritis manifesting as DAH, interstitial lung disease (ILD) and asthma (Krause *et al.*, 2012). Major organs involved in MPA are the kidneys and the lungs. The former is manifested by microscopic hematuria, cellular casts in combination with proteinuria (Brusselle, 2007). In 90% of patients, kidneys are involved and is clinically apparent as rapidly progressive glomerulonephritis (Kallenberg, 2014). The incidence of lung involvement in AAV can vary from 30 to 50% of patients with MPA, up to 60% in EGPA and 67 to 85% in GPA (Sacoto *et al.*, 2020). The commonest causes include AAV and anti-GBM disease. Pathophysiology involves predominantly neutrophilic inflammation causing fibrinoid necrosis of the capillary walls with the loss of the integrity of the alveolar-capillary membrane. Erythrocyte extravasation into the alveolar space results in impairment of the gas exchange (Jara *et al.*, 2003). DAH is seen more commonly in MPA as compared to GPA and EGPA. ANCA in MPA are predominantly directed against MPO but in a minority of patients may be directed against proteinase 3 (PR3-ANCA) (Greco *et al.*, 2015). The characteristic renal lesions are

necrotizing crescentic glomerulonephritis (Sacoto *et al.*, 2020; Greco *et al.*, 2015). Focal thrombosis of glomerular capillaries with fibrinoid necrosis is typically followed by rupture of the glomerular basement membrane and extra capillary proliferation resulting in crescent formation (Villiger and Guillevin, 2010). PRS is defined as concurrent autoimmune-induced DAH and RPGN (West *et al.*, 2013; McCabe *et al.*, 2011). Patients can present within a spectrum ranging from asymptomatic radiographic abnormalities to severe life-threatening respiratory failure (McCabe *et al.*, 2011). Signs of alveolar hemorrhage are bilateral opacities, ground-glass pattern, crazy-paving pattern and/or consolidation because of alveolar filling (Greenan *et al.*, 2018). Chest X-ray may fail to reveal anything in upto 50% of the patients and CT scan should be obtained. Bronchoscopy with BAL confirms the presence of intra-alveolar blood and results in an increasingly hemorrhagic appearance of consecutive BAL aliquots in DAH (Sacoto *et al.*, 2020). BAL is the gold standard to confirm alveolar hemorrhage (Park, 2013). PRS does not necessarily require the same treatment in all patients (Papiris *et al.*, 2007). Instead, the severity of involvement of different organs, age of the patient, and prior immunosuppression history are all factors in deciding on the best treatment for an individual patient (Papiris *et al.*, 2007). Treatment is divided into induction of remission and maintenance. Remission induction is commonly achieved with high dose IV methylprednisolone (0.5-1 g/day) for 3-5 days (West *et al.*, 2013). Plasmapheresis has also been used in severe cases; other agents include mycophenolate mofetil, cyclophosphamide, and rituximab (Greco *et al.*, 2015; West *et al.*, 2013). Low-dose glucocorticoids for at least 18 months along with a steroid-sparing agent such as azathioprine or mycophenolate mofetil are the mainstay for maintaining remission (Terrier and Guillevin, 2018). In our patient, inhaled TXA was used for pulmonary hemorrhage; however, more data is needed to conclusively comment on its efficacy in the setting of PRS (Krause *et al.*, 2012). DAH is a very strong predictor of mortality in MPA, increasing the relative risk by up to 8 times (Krause *et al.*, 2012).

Conclusion

PRS often presents with non-specific symptoms requiring high index of suspicion and multidisciplinary input. Once suspected, appropriate autoimmune workup should be undertaken, usually followed by renal biopsy. Prompt initiation of potent immunosuppressants and supportive care form the foundation of treatment. Despite advancement in novel therapeutics, patients remain at a substantial risk for life threatening infections from immunosuppression in the remission phase of treatment.

References

Brusselle GG. Pulmonary-renal syndromes. *Acta Clin Belg* 2007; 62: 88-96.

Greco A, De Virgilio A, Rizzo MI, Gallo A, Magliulo G, Fusconi M, Ruoppolo G, Tombolini M, Turchetta R, de Vincentiis M.

Microscopic polyangiitis: Advances in diagnostic and therapeutic approaches. *Autoimmun Rev* 2015; 14: 837-844.

Greenan K, Vassallo D, Chinnadurai R, Ritchie J, Shepherd K, Green D, Ponnusamy A, Sinha S. Respiratory manifestations of ANCA-associated vasculitis. *Clin Respir J* 2018; 12: 57-61.

Jara LJ, Vera-Lastra O, Calleja MC. Pulmonary-renal vasculitic disorders: differential diagnosis and management. *Curr Rheumatol Rep* 2003; 5: 107-115.

Kallenberg CG. The diagnosis and classification of microscopic polyangiitis. *J Autoimmun* 2014; 49: 90-93.

Krause ML, Cartin-Ceba R, Specks U, Peikert T. Update on diffuse alveolar hemorrhage and pulmonary vasculitis. *Immunol Allergy Clin North Am* 2012; 32: 587-600.

McCabe C, Jones Q, Nikolopoulou A, Wathen C, Luqmani R. Pulmonary-renal syndromes: an update for respiratory physicians. *Respir Med* 2011; 105: 1413-1421.

Papiris SA, Manali ED, Kalomenidis I, Kapotsis GE, Karakatsani A, Roussos C. Bench-to-bedside review: pulmonary-renal syndromes--an update for the intensivist. *Crit Care* 2007; 11: 213.

Park MS. Diffuse Alveolar Hemorrhage. *Tuberc Respir Dis* 2013; 74: 151.

Sacoto G, Boukhhal S, Specks U, Flores-Suárez LF, Cornec D. Lung involvement in ANCA-associated vasculitis. *Presse Med* 2020; 49: 104039.

Terrier B and Guillevin L. Treatment of Pulmonary Vasculitis. *Semin Respir Crit Care Med* 2018; 39: 504–510.

Villiger PM and Guillevin L. Microscopic polyangiitis: Clinical presentation. *Autoimmun Rev* 2010; 9: 812-819.

West SC, Arulkumaran N, Ind PW, Pusey CD. Pulmonary-renal syndrome: a life threatening but treatable condition. *Postgrad Med J* 2013; 89: 274-283.