

Paradoxical Hypocapnia While Wearing a Facemask: A Novel Cause of Orthostatic Intolerance - A Case Report

C. (Linda) M.C. van Campen¹ | Peter C. Rowe² | Frans C. Visser^{1*}

*Correspondence: Frans C Visser

Address: ¹Stichting CardioZorg, Planetenweg 5, 2132 HN Hoofddorp, Netherlands; ²Department of Pediatrics, Johns Hopkins University School of Medicine, Baltimore, MD, USA

e-mail ✉: fransvisser@stichtingcardiozorg.nl

Received: 24 June 2021; Accepted: 05 July 2021

Copyright: © 2021 Van Campen CMC. This is an open-access article distributed under the terms of the Creative Commons Attribution License, which permits unrestricted use, distribution, and reproduction in any medium, provided that the original work is properly cited.

ABSTRACT

Previous studies with facemasks have shown significant respiratory effects, including increased breathing resistance, CO₂ rebreathing due to CO₂ accumulation in the facemask cavity leading to hypercapnia, and decreased inhaled O₂ concentration. These changes may lead to a number of symptoms like dyspnea, headache, sweating, and dizziness. In the present case report a patient is described with similar symptoms while wearing a facemask, but with the opposite effect: a hyperventilatory hypocapnic response, leading to orthostatic intolerance symptoms.

A 34 year old female patient was examined with symptoms while wearing a facemask in public. She was studied in the supine position. First, end-tidal CO₂ and cerebral flow measurements, using extracranial Doppler imaging, were obtained without facemask. Thereafter, after 10 minutes of wearing a facemask, measurements were repeated.

While wearing the facemask, the end-tidal CO₂ decreased from 35 mmHg without the facemask to 28 mmHg with the facemask, respiration rate increased from 10 to 15 breath/min and cerebral blood flow decreased from 565 ml/min to 419 ml/min, a 26% reduction while wearing the facemask. These changes were accompanied by her typical orthostatic intolerance symptoms while wearing the facemask in public

As shown in this patient, wearing a facemask cannot only cause hypercapnia, as has been previously described, but may also cause hypocapnia, leading to a cerebral blood flow reduction and orthostatic intolerance symptoms.

Keywords: Facemask, Extracranial Doppler Imaging, Cerebral Blood Flow, End-Tidal CO₂, Hypocapnia

Introduction

In the SARS-CoV2 era, some people experience dyspnea, dizziness, palpitations and a general feeling of discomfort while wearing a facemask in public areas, symptoms that are not present without wearing the facemask. Previous studies have shown that facemasks can exert significant respiratory effects, including increased breathing resistance, CO₂ rebreathing due to CO₂ accumulation in the

facemask cavity, and decreased inhaled O₂ concentration (Johnson, 2016). CO₂ rebreathing can result in hypercapnia and lead to dyspnea, headache, sweating, and dizziness, even in individuals without medical diseases (Johnson, 2016). Similar symptoms can also accompany orthostatic intolerance (van Campen *et al.*, 2020), often in the presence of hypocapnia. We evaluated a patient whose symptoms occurred while wearing a facemask. To assess whether symptoms were associated with hyper- or hypocapnia, we measured cerebral blood flow (CBF) measurements using extracranial Doppler, in combination with end-tidal CO₂ pressure (PetCO₂) assessment with and without wearing a facemask.

Case Report

A 34 year old female patient with previously diagnosed myalgic encephalomyelitis/chronic fatigue syndrome (ME/CFS) and proven orthostatic intolerance developed symptoms acutely after putting on a facemask in shops. She experienced immediate onset of an increased respiratory rate, followed by a tingling feeling in the head, increased tension in the shoulder muscles radiating to the neck and head, and an increased pressure sensation within the head. She often reported associated chest pressure and near-syncope. Within 3 minutes she usually had to remove the facemask. Doing so was associated with a gradual relief of symptoms. Her facemask is commercially available, custom-made, consisting of three layers of 100% cotton, without a filter.

To evaluate her symptoms, we measured cerebral blood flow (CBF) by extracranial Doppler of the internal carotid and vertebral arteries, using a Vivid-I system (GE Healthcare, Hoevelaken, the Netherlands). PetCO₂, heart rate, respiration rate and O₂ saturation were measured using a Lifesense device (Nonin Medical, Minneapolis USA). First, measurements were performed in the supine position, with the facemask off, after 10 minutes of resting. Then, the mask was put on and measurements were repeated in the supine position after 10 minutes. The methodology to measure CBF have been described previously (van Campen *et al.*, 2020). In short, high resolution B mode images, color Doppler images and the Doppler velocity spectrum (pulsed wave mode) were recorded in one frame of the two internal carotid (ICA) and the two vertebral arteries (VA). Blood flow in the individual vessels was calculated from the mean blood flow velocities x the vessel surface area. CBF was the sum of the 4 vessels.

Without the facemask, her mean PetCO₂ was 35 mmHg, heart rate 72 bpm, respiratory rate 10 breaths per min, and O₂ saturation 97%. While wearing the face mask the PetCO₂ gradually decreased to 28 mmHg, heart rate gradually increased to 83 bpm, respiration rate increased to 15 breaths/min and O₂ saturation increased to 98%. After 10 min of wearing the facemask she developed the typical complaints she experiences while shopping.

Fig. 1 shows the flow velocity profiles with extracranial Doppler of the 2 carotid and 2 vertebral arteries without facemask (left panels) and with facemask (right panels). Flow in the left ICA decreased from 174 ml/min without facemask to 121 ml/min while wearing the mask, in the right ICA from 219 to 174 ml/min, in the left VA from 56 to 40 ml/min, in the right VA from 116 to 84 ml/min. Total CBF without the facemask was 565 ml/min, and with facemask was 419 ml/min, a 26% CBF reduction while wearing the facemask. Table 1 shows the results of the mean flow velocities in the 4 arteries supine without facemask (left column) and supine with facemask (right column).

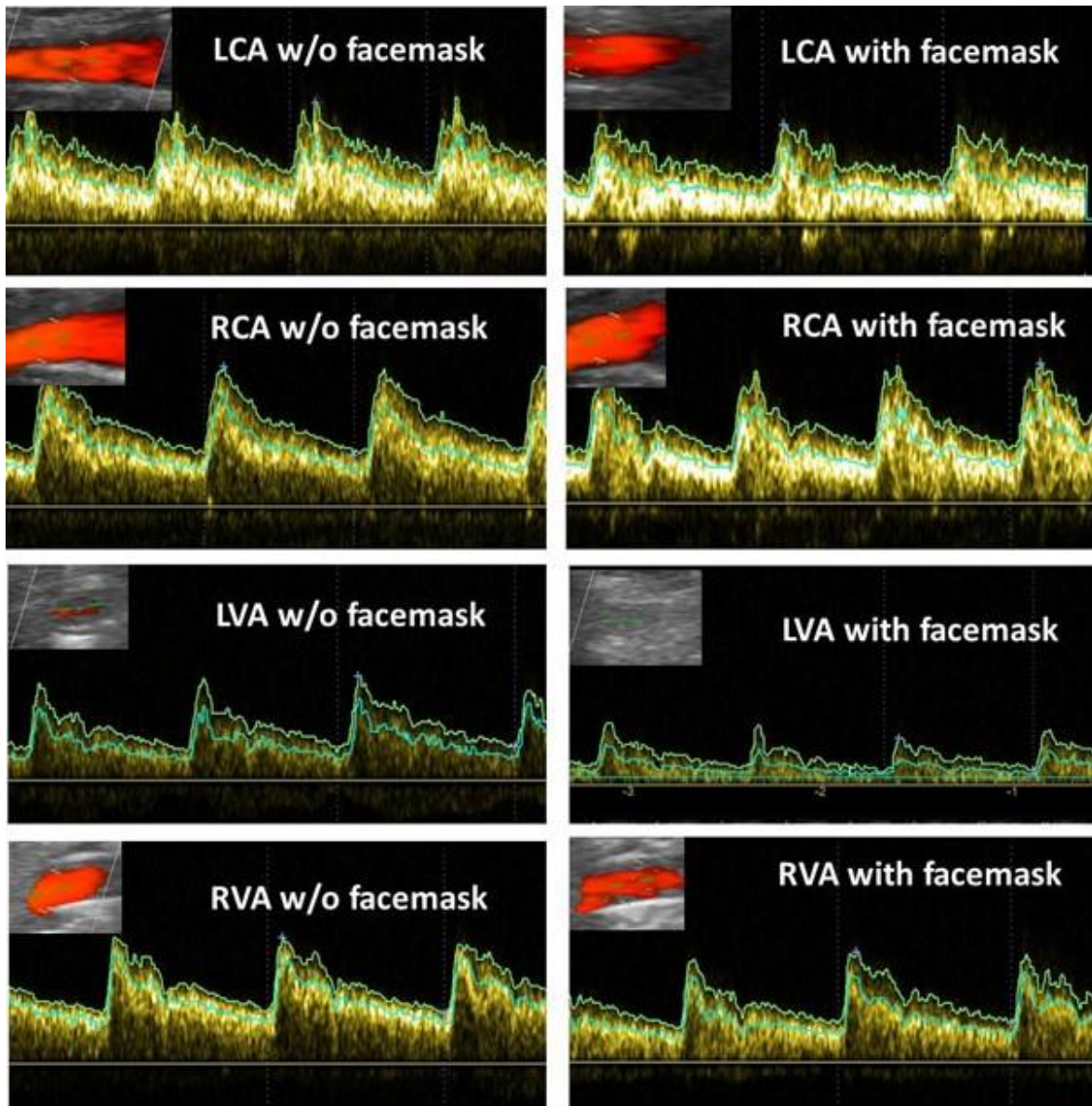


Figure 1: Cerebral arteries and their flow velocity profiles

Doppler flow velocity profiles are shown in the figure for each vessel. Vessel flows are shown in the inserts top left. The upper light green line in the velocity profiles indicate the peak flow velocities, the green lines below indicate the mean flow velocities.

LCA: left carotid artery; RCA: right carotid artery; LVA: left vertebral artery; RVA: right vertebral artery.

Table 1: Mean flow velocity measurements supine without and with facemask

Supine mean flow velocities (cm/sec)	Without Facemask	With Facemask
Left Carotid Artery (LCA)	26.72	21.96
Right Carotid Artery (RCA)	34.24	19.99
Left Vertebral Artery (LVA)	19.02	12.61
Right Vertebral Artery (RVA)	26.6	19.21

Discussion

Prior research suggests that symptoms associated with wearing a facemask are related to a reduction in O₂ uptake and/or increased PaCO₂ (Perna *et al.*, 2020). The primary response of our patient was a hypocapnic hyperventilatory response while wearing the facemask: O₂ saturation and respiration rate increased, and PetCO₂ decreased (Stewart *et al.*, 2018).

Many studies have shown that CO₂ changes profoundly change cerebral flow and vasoreactivity: see for an extensive review Hoiland, *et al.* (2011). A PaCO₂ reduction leads to vasoconstriction of the intracranial arteries and thus to reduction of CBF and development of orthostatic intolerance symptoms, as shown in this patient (Hoiland *et al.*, 2011).

Clinical Implications: Wearing a facemask cannot only cause hypercapnia, but, as shown in this patient, may also cause hypocapnia. The mechanism of the hypocapnia as well as the prevalence of this response and whether it is associated with orthostatic intolerance all remain to be studied.

Conflicts of Interest: None for all authors

Funding: No funding

Ethics Statement: The study was conducted according to the guidelines of the Declaration of Helsinki, and approved by the Institutional Review Board (or Ethics Committee) of the Slotervaart Hospital (protocol code P1411 and date of approval 14 march 2014).

References

Hoiland RL, Fisher JA, Ainslie PN. Regulation of the cerebral circulation by arterial carbon dioxide. *Compr Physiol* 2011; 9: 1101-1154.

Johnson AT. Respirator masks protect health but impact performance: a review. *J Biol Eng* 2016; 10: 1-2.

Perna G, Cuniberti F, Daccò S, Nobile M, Caldirola D. Impact of respiratory protective devices on respiration: Implications for panic vulnerability during the COVID-19 pandemic. *J Affect Disord* 2020; 277:

772-778.

Stewart JM, Pianosi P, Shaban MA, Terilli C, Svistunova M, Visintainer P, Medow MS. Postural hyperventilation as a cause of postural tachycardia syndrome: increased systemic vascular resistance and decreased cardiac output when upright in all postural tachycardia syndrome variants. *J Am Heart Assoc* 2018; 7: e008854.

van Campen CL, Verheugt FW, Rowe PC, Visser FC. Cerebral blood flow is reduced in ME/CFS during head-up tilt testing even in the absence of hypotension or tachycardia: a quantitative, controlled study using Doppler echography. *Clin Neurophysiol Pract* 2020; 5: 50-58.